

# Osseous injuries of the foot: an imaging review. Part 1: the forefoot

Alexander James Kiener,<sup>1</sup> Tarek N Hanna,<sup>2</sup> Waqas Shuaib,<sup>2</sup> Abhijit Datir,<sup>3</sup>  
Faisal Khosa<sup>2</sup>

<sup>1</sup>Emory University School of Medicine, Atlanta, Georgia, USA

<sup>2</sup>Division of Emergency Radiology, Department of Radiology and Imaging Sciences, Emory University School of Medicine, Atlanta, Georgia, USA

<sup>3</sup>Division of Musculoskeletal Radiology, Department of Radiology and Imaging Sciences, Emory University School of Medicine, Atlanta, Georgia, USA

## Correspondence to

Dr Tarek N Hanna, Division of Emergency Radiology, Department of Radiology and Imaging Sciences, Emory University Midtown Hospital, 550 Peachtree Road, Atlanta GA 30308, USA; [tarek.hanna@emory.edu](mailto:tarek.hanna@emory.edu)

Received 5 March 2015

Revised 16 December 2015

Accepted 17 January 2016

## ABSTRACT

Injuries to the foot are a common cause for presentation to the ED, and imaging is often used to aid in the diagnosis. The foot can be divided into three distinct anatomical regions: the forefoot, midfoot and hindfoot. Our manuscripts comprise a three-part imaging review in which we address the use of radiography as well as advanced imaging modalities. We provide pearls to radiographic interpretation and discuss prognostic implications and classification systems. Part 1 addresses forefoot injuries, part 2 reviews midfoot injuries and part 3 covers the hindfoot.

## INTRODUCTION

This three-part series will focus on the imaging approach to fractures and injuries of the foot. Foot injuries are very common and fractures of the foot account for 10% of all fractures.<sup>1</sup> This first article of our series focuses on the forefoot, which is commonly involved in trauma and accounts for up to 80% of all traumatic injuries to the ankle and foot.<sup>2</sup> These injuries have the potential to cause long-lasting morbidity if not diagnosed and treated in a timely manner.<sup>2</sup> The forefoot is composed of the five metatarsals and the phalanges. The great toe has two phalanges, and each of the lesser toes most commonly has three phalanges although they may occasionally have only two phalanges (most common in the fifth toe). This article will review forefoot osseous injuries in the adult with an emphasis on radiological imaging.

The forefoot is instrumental in the action of normal gait, and a basic understanding of physiological biomechanics can help providers become aware of the importance of forefoot injuries. Conceptualising the normal gait breaks it down into heel strike, forefoot contact, heel lift, peak forefoot loading (which occurs with metatarsal-phalangeal (MTP) joint extension) followed by toe lift-off as the foot leaves the floor. The first metatarsal is the most heavily loaded structure of the forefoot, with the first metatarsal head bearing a total force of approximately 120% of body weight during ambulation.<sup>3</sup> The first metatarsal is instrumental in supporting the longitudinal arch of the foot during gait, and the great toe aids in providing stability during maximal forefoot loading.<sup>3</sup> If the first metatarsal fails, the second metatarsal is often unequipped to handle the added stress and will likely also fail.<sup>3</sup> The first MTP joint is inherently well supported by ligamentous and muscular structures and the great toe is also important to the biomechanics of locomotion.<sup>4</sup> This central function of the great toe and first metatarsal to the actions of

the forefoot, which also necessitate dynamic movement, are the reasons that fractures of the first metatarsal and great toe are of central importance.

## FOREFOOT INJURIES

In general, a standard three-view foot series should be obtained for initial imaging evaluation of forefoot injury (figure 1). A standard search algorithm should be used to evaluate all foot radiographs—both to avoid missing subtle injuries and to avoid satisfaction of search, in which the presence of one injury compromises detection of a second. The authors suggest starting with evaluation of the hindfoot on the lateral view, looking at the calcaneus and talus, as well as the imaged distal tibia and fibula. The oblique view should be used as a complimentary view in evaluation of the hindfoot. Subsequently, the clinician can move their eyes anteriorly, interrogating the navicular, cuboid and cuneiforms. The oblique and anteroposterior (AP) views are most helpful in this regard. The tarsal-metatarsal joints should then be evaluated individually, with particular attention paid to the first and second tarsal-metatarsal joints. At this point, the metatarsals should be evaluated individually, from proximal to distal (primarily on AP and oblique views). Finally, the toes should be viewed in a similar fashion.

## Metatarsal fractures

There are five metatarsal bones in each foot. Due to the anatomic relationship of the bones, it is useful to discuss injuries to the metatarsals in three groups: the first metatarsal, the central metatarsals (M2–M4) and the fifth metatarsal. Each of the metatarsals has distinct sections including, from most proximal to most distal, the metatarsal base (proximal epiphysis), the proximal metaphysis, the diaphysis or shaft, the neck (distal metaphysis) and the head (distal epiphysis). Fractures of the metatarsal bones comprise a significant proportion of injuries to the foot causing acute forefoot pain. Injuries to these bones are usually the result of direct trauma or a twisting force.<sup>5</sup> Approximately 9% of metatarsal fractures are caused by injuries sustained during sports.<sup>6</sup> Acute fractures can affect any portion of the metatarsal bones.

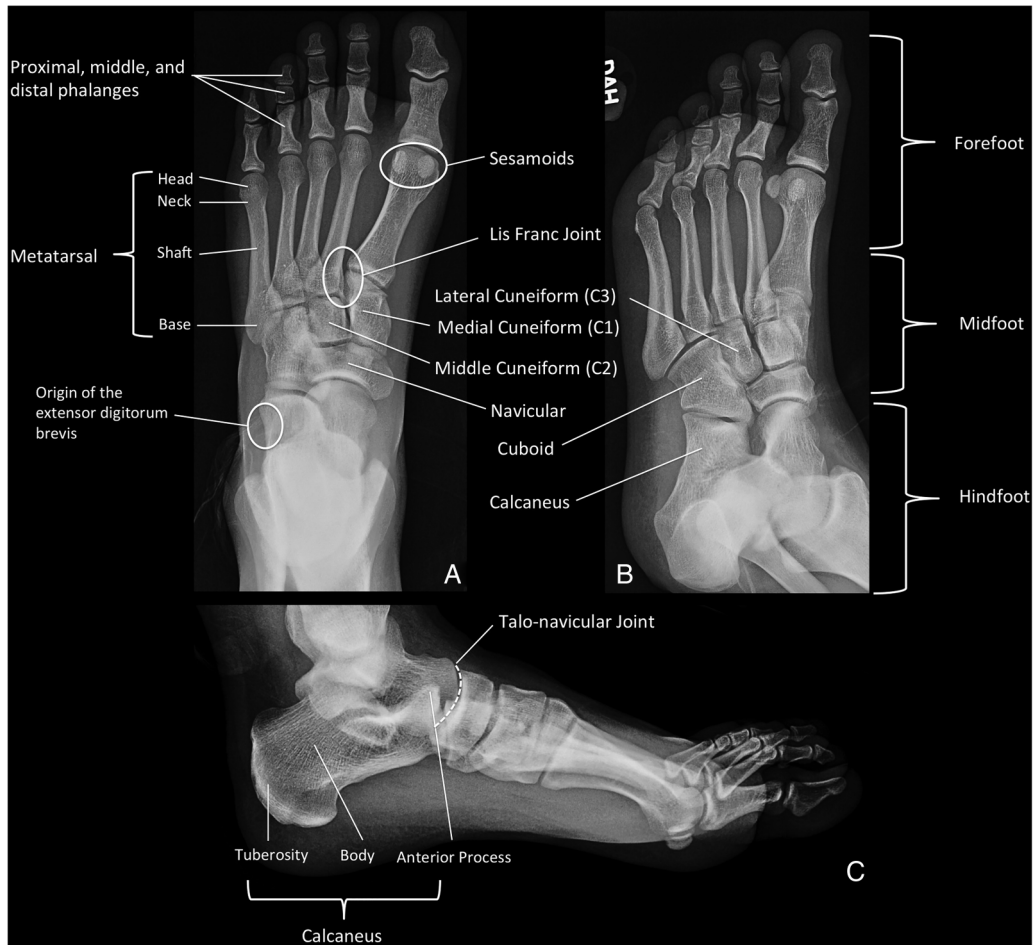
Stress fractures (abnormal stress on normal bone) or insufficiency fractures (normal stress on abnormally weak bone) most often occur in the metatarsal shafts and although early plain radiograph evaluation of stress fractures may not show evidence of pathology, over time the fractures become more obvious due to periosteal reaction and eventually smooth cortical thickening (figure 2).<sup>7</sup>



► <http://dx.doi.org/10.1136/emmermed-2016-205704>

► <http://dx.doi.org/10.1136/emmermed-2016-205706>

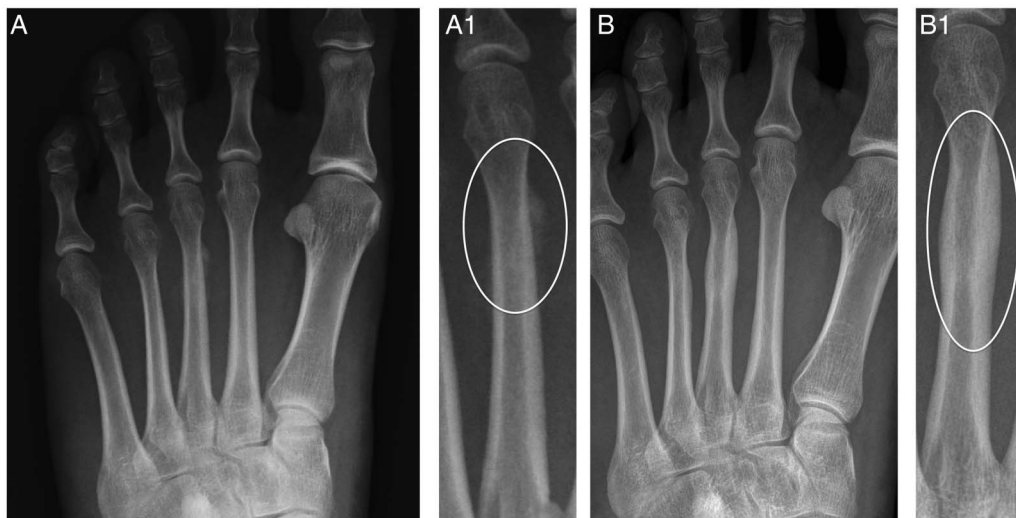**To cite:** Kiener AJ, Hanna TN, Shuaib W, et al. *Emerg Med J* Published Online First: [please include Day Month Year] doi:10.1136/emmermed-2015-204807



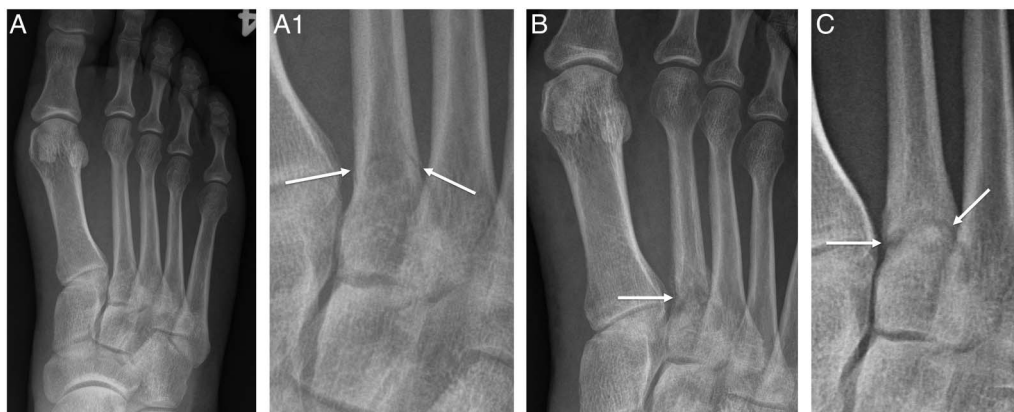**Figure 1** Normal three-view foot radiographs, anteroposterior (A), oblique (B) and lateral (C).

For stress fractures, an appropriate clinical history of overuse combined with point tenderness and pain on exertion should lead to suspicion for such an injury. Insufficiency injuries can be more difficult to identify clinically, but are seen in patients with

osteoporosis who have subacute to chronic pain following normal activities of daily living. Insufficiency fractures will have the same radiographic appearance as stress fractures, except that the background bone will be osteoporotic in these patients.



**Figure 2** A 25-year-old runner who presented to the ED with foot pain. Foot radiograph (A) and magnified third metatarsal (A1) demonstrate smooth periosteal reaction involving the distal diaphysis of the third metatarsal (circle), compatible with stress fracture. (B) and (B1) are radiographs from the same patient obtained 8 months later. There is smooth cortical thickening involved in the distal diaphysis of the third metatarsal (circle), compatible with healed stress fracture.



**Figure 3** A 48-year-old male presented following jump from height. Initial right foot radiograph (A) and magnification view (A1) show a very subtle fracture of the proximal metaphysis of the second metatarsal (arrows), which was missed on initial radiographs. (B) Radiograph obtained 4 months later, after persistent pain, with lucency and remodelling of the proximal metaphysis and local periosteal new bone formation, compatible with attempted fracture healing. (C) Radiograph obtained at a follow-up clinic visit 7 months after the initial injury shows progression to pseudoarthrosis, with a thick lucent fracture line, and rounded edges which are corticating. Patient eventually underwent surgical repair.

#### First metatarsal

The first metatarsal is a weight-bearing segment of the medial column of the foot. Thus, correct evaluation and management of injuries to the first metatarsal are important in restoring stability and minimising morbidity. Although it is overall the least commonly injured of the metatarsals, the first metatarsal is the most commonly fractured in young children, thought to be due to a frequent type of injury being a fall from height.<sup>8</sup> Falls and direct blows are the most common causes and most frequently result in diaphyseal fractures.<sup>9</sup> Displaced fractures of the first metatarsal neck require early referral for open reduction and fixation, while non-displaced stable fractures are often successfully treated with immobilisation via casting for 4–6 weeks.<sup>1</sup> Crush injuries as well as avulsion fractures of the metatarsal base have also been described but are less common.

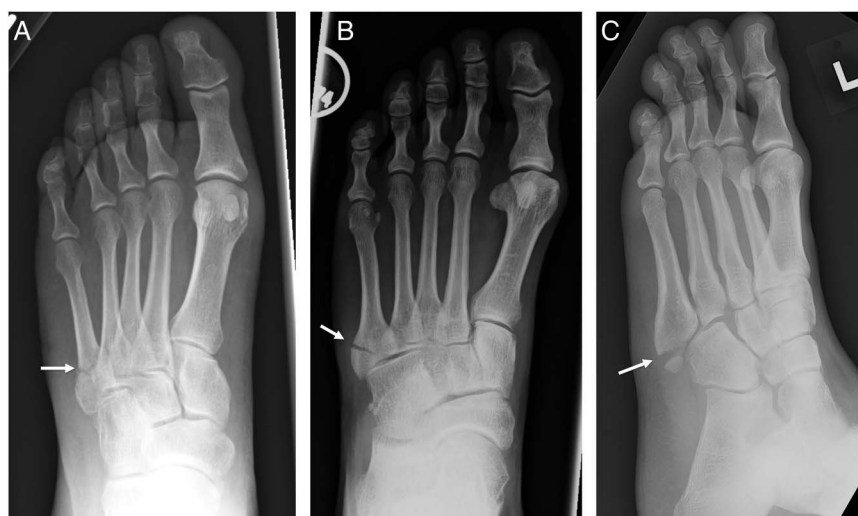
#### Central metatarsals

Careful radiographic evaluation is necessary when there is concern for a central metatarsal fracture (figure 3). This evaluation is needed because the majority of the time these fractures are not isolated to one metatarsal;<sup>9</sup> thus, identification of a single displaced metatarsal fracture should prompt very close

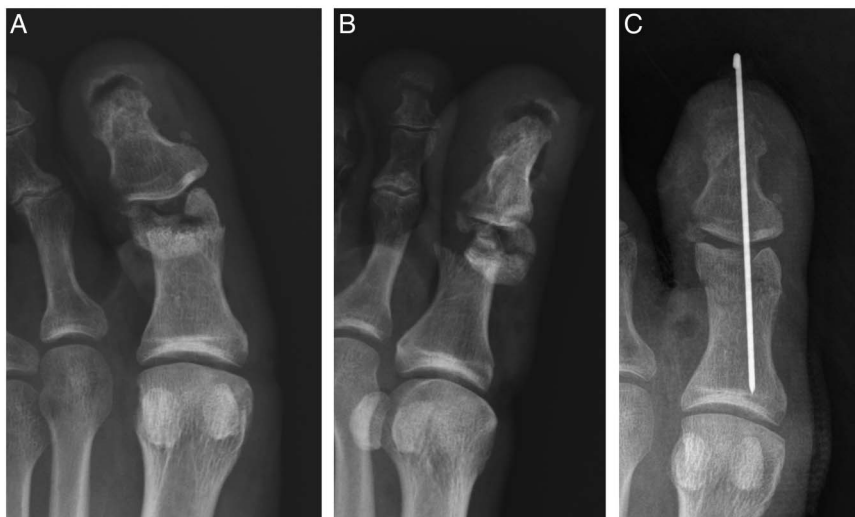inspection of the adjacent metatarsals for concomitant non-displaced fractures. Isolated metatarsal fractures, often diaphyseal fractures occurring as a result of direct trauma, will usually be non-displaced due to the stabilising effect of the adjacent metatarsals. These fractures are relatively stable and need only conservative treatment unless the fracture fragments are displaced.<sup>5</sup> Displacement  $>3$  mm or angulation  $>10^\circ$  often requires closed reduction, as such deformities if persistent would disrupt the normal weight bearing of the forefoot.<sup>10</sup> The best views for radiographic assessment of shaft fractures are oblique and AP.<sup>7</sup>

Fractures involving or near the metatarsal base should prompt close inspection of the tarsometatarsal joint alignment. In particular, any widening of the first and second metatarsal interspace, or malalignment between the second metatarsal base and the cuneiform is suggestive of a Lisfranc injury. This injury is discussed in greater detail in part 2 of this series. Stress fractures of the base of the second and third metatarsals are classically described in ballet dancers, presumably due to the positioning of the feet during dancing and the propensity to low body weight.<sup>11 12</sup> These injuries may progress to Lisfranc injuries if continued use leads to further damage.<sup>12</sup> Lateral radiographs

**Figure 4** Fractures of the base of the fifth metatarsal. (A) Acute transverse fracture occurring at the proximal metaphysis of the fifth metatarsal, without intra-articular extension, compatible with a Jones fracture (arrow). (B) Fifth metatarsal base fracture with intra-articular extension into the metatarsal-cuboid joint (arrow). This is not technically a Jones fracture, and is often referred to as a pseudo-Jones fracture. (C) Avulsion fracture of the tip of the fifth metatarsal at the attachment of the peroneus brevis (arrow). This fracture also should not be referred to as a Jones fracture.



**Figure 5** A 55-year-old man who presented following a lawnmower injury with comminuted great toe fracture with significant involvement of the interphalangeal joint, and fracture displacement (A and B). (C) Radiograph following operative irrigation and reduction with orthopaedic pinning.



are important to determine if there is any displacement in the sagittal plane.<sup>13</sup>

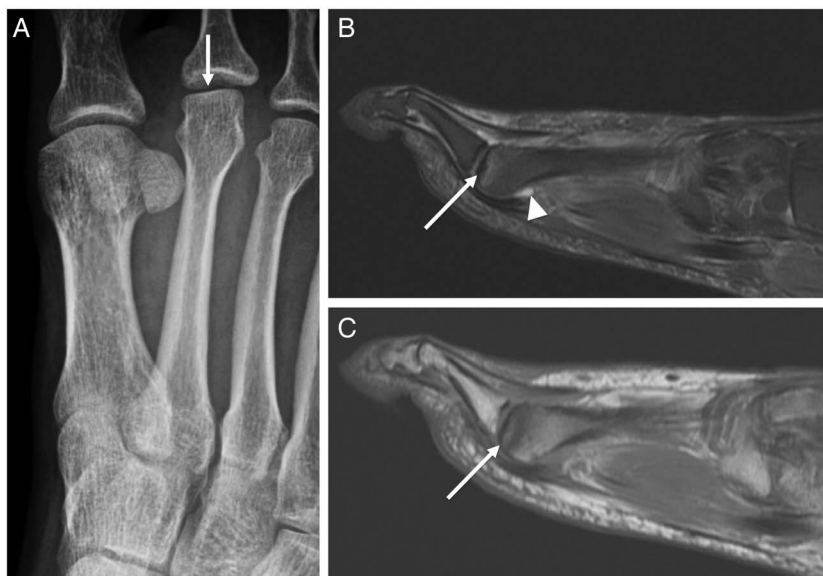#### Fifth metatarsal

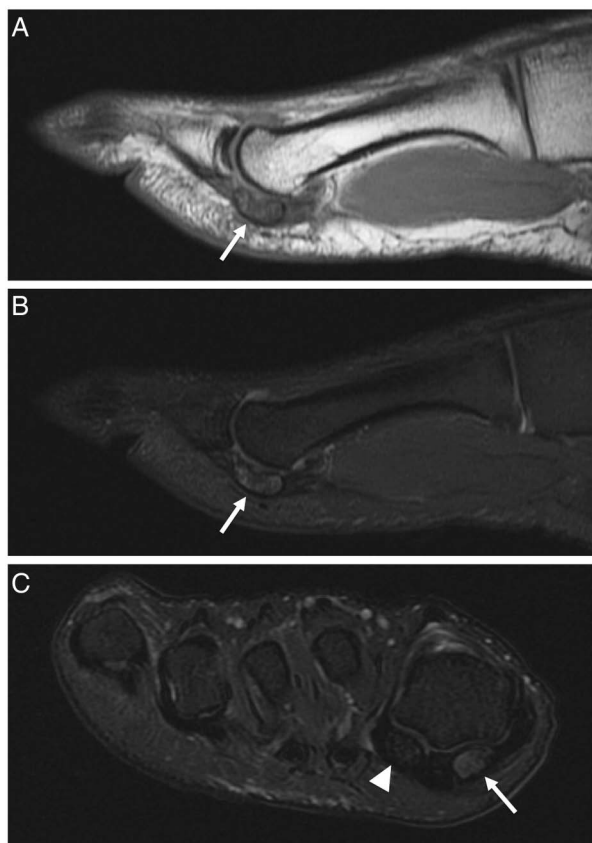
The fifth metatarsal is the most commonly fractured of the metatarsals. Fractures can occur anywhere along the bone. Fractures of the neck can be transverse, spiral or impacted while fractures of the diaphysis are usually spiral. Radiographic evaluation often shows a butterfly fragment, but comminution is possible with direct trauma and suboptimal quality of bone.<sup>9</sup> Isolated fractures that occur at the metatarsal bases are relatively common injuries, with a fracture at the base of the fifth metatarsal being the most common of all (figure 4). The *Jones fracture* eponym technically refers to fractures occurring 2 cm from the fifth metatarsal base.<sup>12–14</sup> Avulsion injuries of the fifth metatarsal occur by indirect force on the plantar flexed and inverted foot, with avulsion mechanism secondary to force at the peroneus brevis attachment; such fractures are more correctly termed pseudo-Jones or dancer's fractures, although the term Jones fracture is applied liberally in practice and in the literature.<sup>15</sup> Radiographically, this avulsion fracture usually does not extend into the metatarsocuboid or fourth–fifth metatarsal articulations.

Fractures to the fifth metatarsal base are common in athletes, with soccer players having the highest rate of metatarsal fractures.<sup>6</sup> With regards to treatment, the avulsion injury of the fifth metatarsal base has a high rate of bony union and is usually treated non-operatively with immobilisation via walking boot. Jones fractures, on the other hand, have a higher risk of delayed union, non-union or repeat fracture and thus are often treated surgically. This risk of delayed union or non-union in conservatively treated Jones fractures is likely secondary to a combination of limited vascularity in this region of bone and repetitive local stress during activity.

On radiographs, providers should be aware of the possibility of small accessory bones off the base of the fifth metatarsal. Two types of accessory bones os peroneum and os vesalianum have a prevalence of up to 26% and <1%, respectively.<sup>16</sup> In contrast to a fragment resulting from a fracture, these accessory bones will look smooth and have cortex around the circumference (well corticated). Teens may also have an apophysis present on the lateral portion of the tuberosity.<sup>7</sup> CT or MRI may be needed in complex or difficult cases, especially when soft tissue injury (such as peroneus brevis rupture) is suspected.

**Figure 6** A 54-year-old female with forefoot pain. (A) Radiographs obtained in the ED show very subtle flattening of the head of the second metatarsal (arrow). (B) Sagittal proton density fat saturated and (C) sagittal proton density sequences through the second metatarsal head. There is a small amount of effusion in the second metatarsal–phalangeal joint (arrowhead). There is flattening of the subchondral bone at the second metatarsal head, with subchondral bony oedema and sclerosis. Findings are compatible with Freiberg's infraction.





**Figure 7** A 21-year-old soccer player presenting with severe progressive pain at the plantar surface of the great toe metatarsal–phalangeal (MTP) joint. Sagittal proton-density (PD) image (A) and sagittal PD fat saturated (PDFS) image (B) at the level of the medial sesamoid demonstrate hypointense PD marrow signal with corresponding PDFS hyperintensity (arrows). This signal appearance is compatible with marrow oedema in the medial sesamoid. (C) Coronal plane PDFS through the sesamoids allows comparison of the normal lateral sesamoid (arrowhead) with the oedematous medial sesamoid (arrow). This imaging appearance is compatible with sesamoiditis. Note that in the acute post-traumatic setting, a bone contusion has the same imaging characteristics by MRI.

### Phalanges fractures

Phalanx fractures are the most common of all forefoot fractures, and fractures of the lesser phalanges are common and the result of axial force, crush injury or joint hyperflexion.<sup>1 17</sup> Most fractures are either non-displaced or minimally displaced and can be treated conservatively with immobilisation by dynamic splinting (ie, ‘buddy taping’) to an adjacent, non-fractured phalanx for stabilisation. Displaced fractures often need closed reduction in addition to immobilisation.<sup>18</sup> Intra-articular fractures which extend into the interphalangeal or MTP joints are more likely to develop complications including arthritis.<sup>17</sup> Great toe fractures require orthopaedic referral more than fractures of lesser toes because of the great toe’s importance in weight bearing (figure 5).<sup>1</sup> If a great toe fracture involves >25% of the joint space, referral is recommended.<sup>1</sup>

### First MTP joint injuries

#### Turf toe

‘Turf toe’ refers to a plantar capsular sprain of the first MTP joint. The plantar plate is an attachment from the proximal phalanx that blends into the sesamoids and the flexor hallucis

longus tendon.<sup>19</sup> The injury occurs due to an axial loading force onto a plantar flexed foot with a maximally extended hallux, leading to hyperextension of the joint. The name arises from a propensity for this injury to occur during sports such as football and soccer played with flexible shoes on artificial turf. Radiographs are frequently negative, sometimes showing focal soft tissue swelling around the great toe MTP joint. Very rarely, turf toe can result in traumatic proximal displacement of one or both sesamoids by radiography. The need to proceed to MRI should be based on clinical features, and often requires an orthopaedic referral from the ED. MRI findings will vary based on severity of the injury but range from discontinuity of the plantar plate due to a full thickness tear, to thinning or thickening of the plantar plate with sprains or partial tears. Proximal retraction of the sesamoids may also be seen in full tears, and may be the only radiographic finding other than soft tissue swelling. Oedema on MRI will be present in acute injuries, in contrast to lack of oedema and possible ossification or osteophytes in chronic injuries.<sup>20</sup>

#### Skimboarder’s toe

‘Skimboarder’s toe’ can also result from hyperdorsiflexion of the first MTP joint. This motion places force onto the extensor expansion, the fibrous tissue extending from the joint capsule through which the flexor hallucis longus tendon transverses.<sup>21</sup> This type of injury is seen in skimboarding (a board sport where a thin board without fins is used to glide across shallow water) when the board slips out posteriorly relative to the rider. MRI is helpful in showing soft tissue oedema and disruption of the dorsal part of the extensor expansion.<sup>21</sup> Although the mechanism of injury is similar to turf toe, the location of the damage in ‘skimboarder’s toe’ is the dorsum of the first MTP joint in the extensor expansion, in contrast to the plantar capsule localisation of the ‘turf toe’ injury. Finally, this is distinguished from a ‘sand toe’ injury which involves extreme *plantar*flexion of the first MTP and involves damage to the dorsum of the joint capsule, similar to that of ‘skimboarder’s toe’.<sup>20 22</sup>

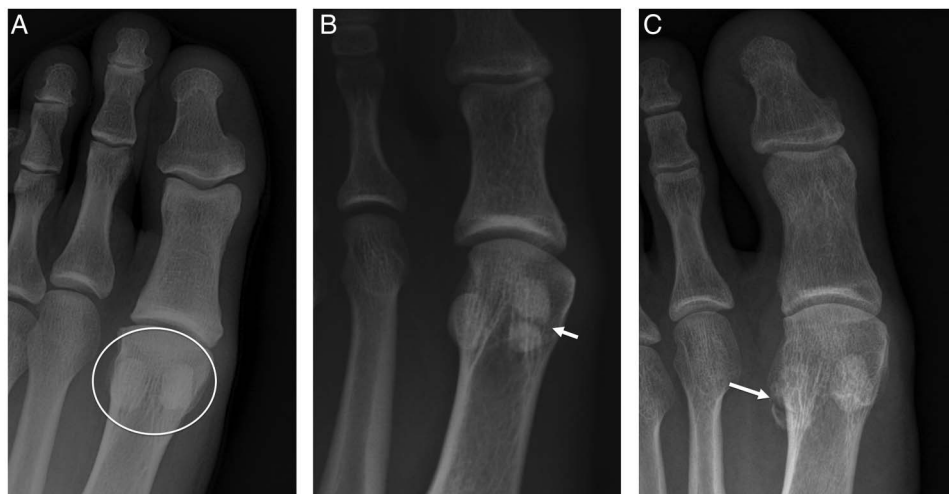#### Freiberg’s infraction

Freiberg’s infraction refers to the cartilaginous and osseous degeneration and collapse of the lesser metatarsal heads.<sup>23</sup> The condition is classically described in teenage females, but can occur in both sexes. The second and third metatarsal heads are more commonly involved than the fourth and fifth metatarsals. The aetiology is unknown but likely is multifactorial, particularly chronic repetitive microtrauma and vascular insufficiency. Aetiologies hypothesised include vascular compromise of the osseous capillary network due to insufficiency of dorsalis pedis and metatarsal arteries, genetic predisposition and altered foot biomechanics of a valgus hallux leading to less support from the medial column and more force dispersed on the lesser metatarsals.<sup>23</sup> Diagnosis is usually clinical with confirmation from radiographs. Radiographs reveal condensation, flattening and fracture of the metatarsal head (figure 6). Early disease may be missed on plain film, and thus, MRIs and bone scans may be helpful in detecting these cases.<sup>23</sup>

#### Sesamoid injuries

##### Acute sesamoiditis

Anatomically, sesamoids are bones that are present in the tendons of muscles. Each foot has two sesamoids located in the flexor hallucis brevis, along the plantar surface of the head of the first metatarsal and termed medial and lateral sesamoids. The sesamoids serve to transfer the force of the muscle in a



**Figure 8** Normal sesamoid (A) (circled), bipartite medial sesamoid (B) and fractured lateral sesamoid (C). Notice how the bipartite sesamoid (B) has rounded, smooth margined portions which do not clearly fit together (arrow). By contrast the sesamoid fracture (C) is sharp, crescentic and fits nicely into the distal donor site (arrow).

different direction, much like a pulley. In some people, bipartite and tripartite sesamoids can be present and may challenge the diagnosis of sesamoid pathology. Sesamoiditis has been noted to be more common in teens and young adults.<sup>24</sup> Sesamoiditis can result from a variety of causes including chronic repetitive stress, chondrosis and degenerative joint disease and avascular necrosis. The condition more commonly affects the medial sesamoid. On imaging, acute stress-related changes may first present with bone oedema on MRI (figure 7). Changes of acute sesamoiditis often have a normal radiographic appearance, and patient symptoms and physical examination findings of focal pain are needed to result in orthopaedic referral or MRI. Chronic sesamoiditis or chronic repetitive stress can lead to sesamoid sclerosis, which may be visible on radiography. Avascular necrosis of the sesamoid is uncommon, but can also appear similar to stress-related changes and contrast-enhanced MRI may be helpful to differentiate the two. Imaging of chondrosis will show subchondral marrow oedema on either the head of the first metatarsal or in the sesamoid. Bone scan can be useful to localise pathology to the sesamoid, but may be falsely negative in mild cases.<sup>20</sup>

#### Acute sesamoid fractures

Sesamoid fracture can result from direct trauma to the plantar aspect of the first metatarsal head. It can be challenging to differentiate a fracture from a bipartite or tripartite. Bipartite sesamoids tend not to fit together perfectly, having reticulated or saw-tooth margins, which can be a helpful differentiating factor;<sup>16 24</sup> an acute fracture will have sharp margins, and the portions of the sesamoid will fit together like parts of a broken plate (figure 8). Other helpful clues that signify a fracture are increased uptake on a bone scan and bone marrow oedema on MRI.<sup>16</sup> The lateral sesamoid is best visualised in the lateral oblique view and the medial sesamoid is best visualised in the medial oblique view. The axial sesamoid view can also be helpful when looking for sesamoid pathology.<sup>24</sup>

#### Flexor/extensor tendon rupture

Rupture of the extensor or flexor tendon of the foot occurs in degeneration, repetitive microtrauma, infection or systemic diseases including diabetes mellitus.<sup>25</sup> These conditions weaken the

tendon and increase the likelihood of atraumatic rupture. Normal tendons may also rupture due to traumatic laceration. Injuries to the extensor tendons are rare. Of the over 1000 cases of tendon rupture analysed in one study, only 16 were in the extensors of the foot and all of those injuries were due to laceration of the extensor tendons.<sup>26</sup> Clinically, if there is concern for flexor tendon rupture based on patient presentation and functional limitations, orthopaedic referral would be needed, and MRI without contrast would provide definitive imaging evaluation. These patients may present with pain, instability and loss of function; some will describe acute popping/snapping at the time of injury. On MRI, tendon ruptures will show discontinuity of the involved tendon. Partial ruptures will show increased signal intensity on MRI, compatible with oedema/fluid interdigitating in the torn tendon fibres.

**Competing interests** FK is the American Roentgen Ray Society Scholar (2013–2016). FK also receives support from NIH Grant 1R56HL126558-01.

**Provenance and peer review** Not commissioned; externally peer reviewed.

#### REFERENCES

- Hanlon D. Foot, in Simon's emergency orthopedics, 7e. In: Sherman SC, ed. New York, NY: McGraw-Hill Education, 2014 <http://accessmergencymedicine.mhmedical.com/content.aspx?bookid=460&sectionid=40703396> (accessed 1/2/2016).
- Clements JR, Schopf R. Advances in forefoot trauma. *Clin Podiatr Med Surg* 2013;30:435–44.
- Jacob HA. Forces acting in the forefoot during normal gait—an estimate. *Clin Biomech (Bristol, Avon)* 2001;16:783–92.
- Lee DK, Mulder GD, Schwartz AK. Hallux, sesamoid, and first metatarsal injuries. *Clin Podiatr Med Surg* 2011;28:43–56.
- Laird RC. Acute forefoot and midfoot injuries. *Clin Podiatr Med Surg* 2015;32:231–8.
- Shuen WMV, Boulton C, Batt ME, et al. Metatarsal fractures and sports. *Surgeon* 2009;7:86–8.
- Hatch RL, Alsobrook JA, Clugston JR. Diagnosis and management of metatarsal fractures. *Am Fam Physician* 2007;76:817–26.
- Singer G, Cichocki M, Schalamon J, et al. A study of metatarsal fractures in children. *J Bone Joint Surg Am* 2008;90:772–6.
- Buddecke DE, Polk MA, Barp EA. Metatarsal fractures. *Clin Podiatr Med Surg* 2010;27:601–24.
- Schenck RC Jr, Heckman JD. Fractures and dislocations of the forefoot: operative and nonoperative treatment. *J Am Acad Orthop Surg* 1995;3:70–78.
- Albisetti W, Perugia D, De Bartolomeo O, et al. Stress fractures of the base of the metatarsal bones in young trainee ballet dancers. *Int Orthop* 2010;34:51–5.
- Brockwell J, Yeung Y, Griffith JF. Stress fractures of the foot and ankle. *Sports Med Arthrosc* 2009;17:149–59.

- 13 Rockwood CA, Green DP, Bucholz RW. *Rockwood and Green's fractures in adults*. 7th edn. Philadelphia, PA: Wolters Kluwer Health/Lippincott Williams & Wilkins, 2010.
- 14 Ramponi DR. Proximal fifth metatarsal fractures. *Adv Emerg Nurs J* 2013;35:287–92.
- 15 Mehlhorn AT, Zwingmann J, Hirschmüller A. *et al*. Radiographic classification for fractures of the fifth metatarsal base. *Skeletal Radiol* 2014;43:467–74.
- 16 Nwawka OK, Hayashi D, Diaz LE, *et al*. Sesamoids and accessory ossicles of the foot: anatomical variability and related pathology. *Insights Imaging* 2013;4:581–93.
- 17 Hatch RL, Hacking S. Evaluation and management of toe fractures. *Am Fam Physician* 2003;68:2413–8.
- 18 Mittlmeier T, Haar P. Sesamoid and toe fractures. *Injury* 2004;35(Suppl 2):Sb87–97.
- 19 Anandan N, Williams PR, Dalavaye SK. Turf toe injury. *Emerg Med J* 2013;30:776–7.
- 20 Schein AJ, Skalski MR, Patel DB, *et al*. Turf toe and sesamoiditis: what the radiologist needs to know. *Clin Imaging* 2015;39:380–9.
- 21 Donnelly LF, Betts JB, Fricke BL. Skimboarder's toe: findings on high-field MRI. *AJR Am J Roentgenol* 2005;184:1481–5.
- 22 Frey C, Andersen GD, Feder KS. Plantarflexion injury to the metatarsophalangeal joint ("sand toe"). *Foot Ankle Int* 1996;17:576–81.
- 23 Talusan PG, Diaz-Collado PJ, Reach JS Jr. Freiberg's infraction: diagnosis and treatment. *Foot Ankle Spec* 2014;7:52–6.
- 24 Anwar R, Anjum SN, Nicholl JE. Sesamoids of the foot. *Current Orthopaedics* 2005;19:40–8.
- 25 Ashman CJ, Klecker RJ, Yu JS. Forefoot pain involving the metatarsal region: differential diagnosis with MR imaging. *Radiographics* 2001;21:1425–40.
- 26 Anzel SH, Covey KW, Weiner AD, *et al*. Disruption of muscles and tendons; an analysis of 1, 014 cases. *Surgery* 1959;45:406–14.



## Osseous injuries of the foot: an imaging review. Part 1: the forefoot

Alexander James Kiener, Tarek N Hanna, Waqas Shuaib, Abhijit Datir and Faisal Khosa

*Emerg Med J* published online March 3, 2016

---

Updated information and services can be found at:

<http://emj.bmj.com/content/early/2016/03/03/emered-2015-204807>

---

*These include:*

### References

This article cites 24 articles, 4 of which you can access for free at: <http://emj.bmj.com/content/early/2016/03/03/emered-2015-204807#BIBL>

### Email alerting service

Receive free email alerts when new articles cite this article. Sign up in the box at the top right corner of the online article.

---

### Topic Collections

Articles on similar topics can be found in the following collections

[Clinical diagnostic tests](#) (1056)  
[Radiology](#) (1002)  
[Radiology \(diagnostics\)](#) (903)  
[Trauma](#) (1047)

---

### Notes

---

To request permissions go to:

<http://group.bmj.com/group/rights-licensing/permissions>

To order reprints go to:

<http://journals.bmj.com/cgi/reprintform>

To subscribe to BMJ go to:

<http://group.bmj.com/subscribe/>